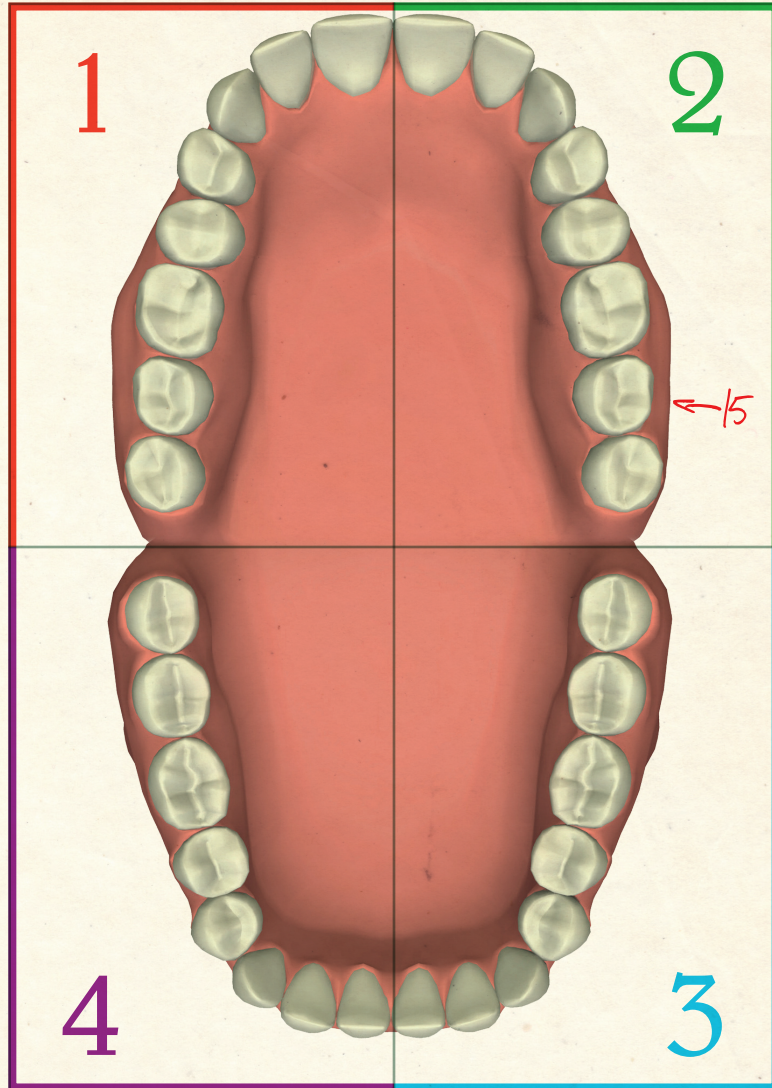


THE ADULT'S



DENTAL QUADRANTS

THE PROTRUDING TONGUE CONCEALS



THE MOLARS THAT A CHILD DOES NOT YET HAVE

